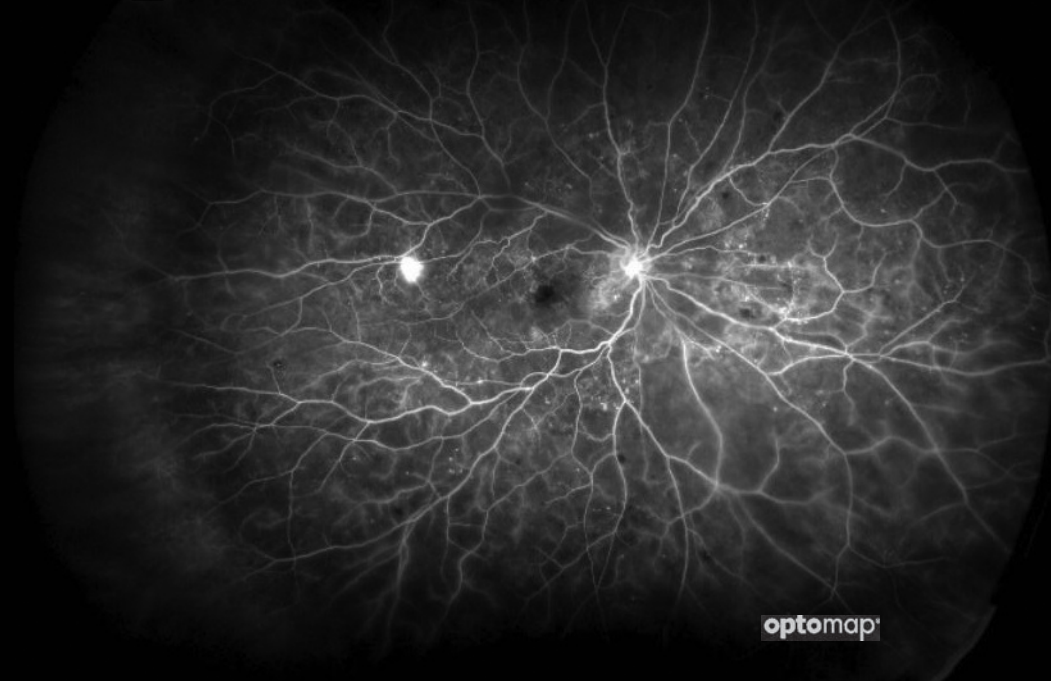


# optomap<sup>®</sup> *fa*

## KEY INDICATOR IN PROGRESSION TO PDR



### Researchers from a clinical study published in JAMA Ophthalmology used optomap *fa* imaging to measure the amount of non-perfusion in patients with NPDR and PDR

Their results indicate that the total area of retinal nonperfusion, specifically in the periphery, is greater in eyes with proliferative diabetic retinopathy (PDR) than in eyes with non-proliferative diabetic retinopathy (NPDR). Researchers found that eyes with at least 107.3 disc areas (DA) of retinal nonperfusion are at risk for proliferative disease. The study also found that eyes with neovascularization of the disc (NVD) had larger areas of non-perfusion.<sup>1</sup>

A second recently published study found similar results with 77.48mm<sup>2</sup> being associated with an increased risk of progression to PDR.<sup>4</sup>

These findings suggest that **optomap *fa*** imaging may improve clinician's ability to identify signs of diabetic retinopathy progression.

*“The difference was predominantly seen in the periphery, with the area of peripheral nonperfusion being significantly higher in eyes with PDR than with NPDR, whereas posterior pole nonperfusion was not significantly different. Although a larger area of retinal nonperfusion has been reported in eyes with PDR, retinal nonperfusion in the periphery appears to be the determining factor in PDR....”*

—JAMA Ophthalmology. 2019

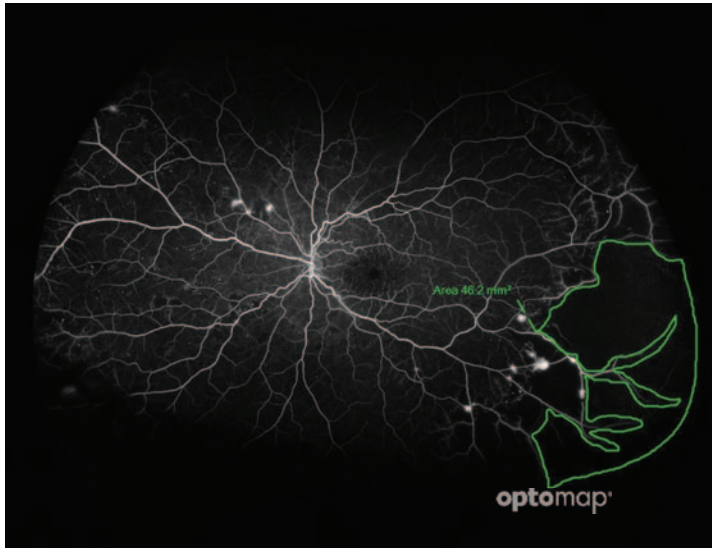
See how **optomap** will help you manage your patients. For more information call **800-854-3039** or email **BDS@optos.com**.



# CLINICAL SUMMARY

## Retinal Nonperfusion Characteristics on Ultra-Widefield Angiography in Eyes With Severe Nonproliferative Diabetic Retinopathy and Proliferative Diabetic Retinopathy

Luke Nicholson, FRCOphth; Jayashree Ramu, MBBS; Errol W. Chan, FRCOphth; James W. Bainbridge, PhD.  
JAMA Ophthalmology | 2019



**optomap fa** demonstrating the anatomically accurate area measurement of peripheral ischemia using *OptosAdvance*.

Researchers performed a statistical analysis of datasets from two previous large multi-center clinical trials (CLARITY and RDP) in which they measured the total disc areas, (DA) of non-perfusion in a set of 92 eyes (59 PDR, 33 NDP), both in the central pole and periphery. Their analysis concluded that eyes with at least 107.3 disc areas of nonperfusion are at risk of proliferative disease. These findings are consistent with previous research which determined that the presence of peripheral lesions increase a patient's risk of progressing to proliferative diabetic retinopathy by a factor of 4.7<sup>2</sup>, and that approximately 70% of non-perfusion occurs outside of the posterior pole.<sup>3</sup>

- A total of 118.3 DA of total retinal capillary nonperfusion is a specific threshold for the identification of PDR.<sup>1</sup>
- Eyes with at least 107.3 disc areas of retinal nonperfusion are at risk for proliferative disease.<sup>1</sup>
- A significant difference was found for peripheral nonperfusion: NPDR eyes measured 64.1 DA and PDR eyes measured 130.6 DA, with a difference of 70.8 DA.
- Another recent study found similar results, indicating that retinal nonperfusion and neovascularization can be effectively quantified on **optomap fa**. They found that these biomarkers may help predict disease progression. Patients who have greater total threshold NP area than 77.48 mm<sup>2</sup>, may have an increased risk of developing PDR (sensitivity of 59.5% and specificity of 73.6%).<sup>4</sup>
- Previous research has reported that the extent of the vasculature can be quantified using **optomap fa** and found that in normal subjects have on average 977mm<sup>2</sup> of retinal vascular bed.<sup>5</sup>
- *OptosAdvance* software allows for the registration of images and monitoring patient's progression over time. Non-perfusion areas can be quantified and compared between visits.

#### References:

1. Retinal Nonperfusion Characteristics on Ultra-Widefield Angiography in Eyes With Severe Nonproliferative Diabetic Retinopathy and Proliferative Diabetic Retinopathy. JAMA Ophthalmology. 2019.
2. Peripheral Lesions Identified on Ultrawide Field Imaging Predict Increased Risk of Diabetic Retinopathy Progression over 4 Years. Ophthalmology 2015.
3. Diabetic retinopathy severity and peripheral lesions are associated with nonperfusion on ultrawide field angiography. Ophthalmology. 2015
4. Quantification of Retinal Nonperfusion and Neovascularization With Ultrawidefield Fluorescein Angiography in Patients With Diabetes and Associated Characteristics of Advanced Disease. JAMA Ophthalmology. 2020.
5. Ultra-widefield Imaging of the Peripheral Retinal Vasculature in Normal Subjects. Ophthalmology. 2016.



**Optos plc**  
Tel: +44 (0)1383 843350  
ics@optos.com

**Optos, Inc.**  
Tel: 800 854 3039  
Tel: 508 787 1400  
usinfo@optos.com

**Optos Australia**  
Tel: +61 8 8444 6500  
auinfo@optos.com

